

Sonography of the Rotator Cuff in Painful Shoulders Performed without Knowledge of Clinical Information: Results from 58 Sonographic Examinations with Surgical Correlation

Stefan Moosmayer, MD,¹ Stig Heir, MD,¹ Hans-Jørgen Smith, MD, PhD²

¹ Department of Orthopaedic Surgery, Martina Hansen's Hospital, P.B. 23, 1306 Bærum Postterminal, Norway

² Department of Radiology, Rikshospitalet-Radiumhospitalet-Radiumhospitalet Medical Center and University of Oslo, 0027 Oslo, Norway

Received 13 January 2006; accepted 1 September 2006

ABSTRACT: *Purpose.* To assess the value of sonography as an isolated diagnostic test for the detection and quantification of rotator cuff tears.

Methods. Preoperative sonographic examination was performed on 58 shoulders. Key biases on sonographic interpretation such as history-taking, physical examination, or concurrent imaging examinations were excluded by way of blinding. Tears of the rotator cuff were the positive findings of interest. Assessment of tear size and localization was done sonographically, and the results were compared with operative findings.

Results. All 24 full-thickness tears observed at surgery had been diagnosed correctly via sonography. In 19 of 20 cases with an intact rotator cuff, preoperative sonography was negative. Thirteen of 14 partial-thickness tears were not detected via sonography; 1 was misinterpreted as a full-thickness tear. Location of the tears relative to the rotator cuff tendons was described correctly in 21 of 25 cases. For tear size measurement, the 95% range of agreement was less than ± 1 cm.

Conclusions. Blinded sonographic examination is effective in the detection and quantification of full-thickness tears of the rotator cuff but lacks sensitivity in the detection of partial-thickness tears. © 2006 Wiley Periodicals, Inc. *J Clin Ultrasound* 35:20–26, 2007; Published online in Wiley InterScience (www.interscience.wiley.com). DOI: 10.1002/jcu.20286

Keywords: diagnostic ultrasound; shoulder; rotator cuff tear; interpretation bias

Sonography as a diagnostic tool for the soft tissues of the shoulder has been available for more than 20 years. Previous studies performed by radiologists and orthopedic surgeons have shown good results for detection of full-thickness tears of the rotator cuff.^{1–7} In these studies, the sonologist was not blinded to the patient's history and clinical findings, making it difficult to interpret the sonographic findings in a completely unbiased fashion. It has been shown that rotator cuff tears can be diagnosed clinically with high accuracy in patients with typical symptoms.^{8–11} Consequently, it can be argued that the unblinded examiner has already formed a clinical diagnosis before assessment of the sonograms. Lack of blinding in earlier studies may have inflated the accuracy of the results from sonography. Although therapeutic decisions cannot be based on sonographic findings taken out of a clinical context, the true value of sonography can only be determined via blinded studies. We investigated the performance of sonography alone in the diagnosis of rotator cuff tears by shielding the sonologist from history-taking and clinical examination findings as well as from the results of alternative imaging studies.

MATERIALS AND METHODS

The study protocol was approved by our institution's ethics committee. From November 2002 to January 2004, 1 orthopedic surgeon (S.M.)

Correspondence to: S. Moosmayer

performed sonographic examination on 350 consecutive shoulder patients. The examiner's experience before this study consisted of 400 sonographic examinations of the shoulder, with a sensitivity of 77% and a specificity of 98% for the detection of full-thickness tears of the rotator cuff in an unblinded setting.¹² Patients were referred by general practitioners for chronic shoulder pain. Sonography was performed as the first-line examination. The examiner was blinded to the patient's history, the findings of physical examination, and the results from MRI and plain radiographs.

Real-time sonography was performed with a Sonoline Sienna scanner (Siemens Ultrasound, Mountain View, CA) equipped with a 5.5–9.4-MHz linear-array transducer. The patient was seated on a swivel stool with the examiner standing behind. Five standard views (anterior transverse, anterior longitudinal, lateral transverse, lateral longitudinal, and posterior transverse) were acquired. For lateral views, the arm was placed in adduction and internal rotation, which gave a better exposure of the supraspinatus tendon from under the acromion. For other views, the arm was placed in adduction and neutral rotation. Dynamic examination was performed, including subscapularis examination under external rotation of the humerus and tendon examination under compression. Bilateral examination was performed in patients with bilateral symptoms. The subscapularis, supraspinatus, infraspinatus, and biceps tendons were assessed in the transverse and longitudinal planes. Diagnostic criteria for pathology of the rotator cuff were used as described in the literature.^{13–15} Criteria for full-thickness tears included nonvisualization of the rotator cuff, hypoechoic or anechoic discontinuity, and contour concavity of the superior border of the rotator cuff tendon. The main criteria for partial-thickness tears were focal heterogeneous hypoechoicity and incomplete hypoechoic clefts. Secondary signs—including double cortex sign, pitting and irregularity of the bony surface of the greater tuberosity, and fluid in the biceps tendon sheath and the subdeltoid bursa—were used as diagnostic aids but were regarded as insufficient to make the diagnosis alone.

Measurement of maximum tear size was made on lateral transverse and longitudinal views. A straight line was used to visualize the distance between the margins of the cuff tear on the lateral transverse view (Figure 1) or between the margin of the tear and the greater tuberosity on the lateral longitudinal view.¹⁶ In cases where the distal margin could not be visualized distal to

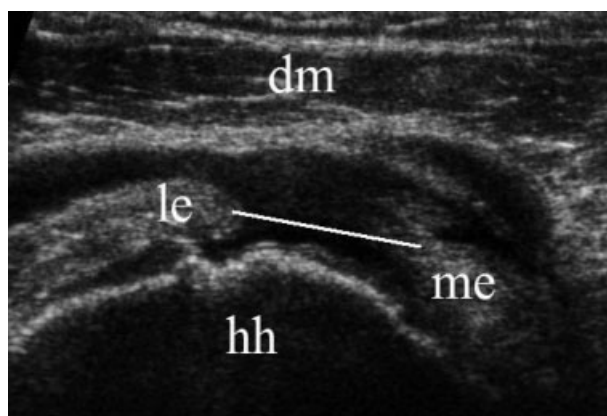


FIGURE 1. Lateral transverse sonogram shows a full-thickness tear of the rotator cuff. A measuring line is drawn between the edges of the tear. Abbreviations: dm, deltoid muscle; hh, humeral head; le, lateral edge of rotator cuff tear; me, medial edge of rotator cuff tear.

the acromion, the cuff was defined as “not visible.” Tear size was not measured in patients presenting with isolated subscapularis tear.

Location of the tears (tendon involved) was determined on anterior (subscapularis) and lateral transverse views (supraspinatus and infraspinatus) using the biceps tendon as a landmark. Tears extending posteriorly less than 1.5 cm from the intra-articular portion of the biceps tendon were recorded as supraspinatus tears. Tears extending over 1.5 cm were recorded as involving both the supraspinatus and infraspinatus. Tears located anterior to the biceps tendon were recorded as subscapularis tears. Tears extending both anterior and posterior to the biceps tendon were recorded as involving the subscapularis and supraspinatus and occasionally the infraspinatus.¹⁷ A form listing the sonographic findings was completed immediately after the examination.

Following completion of the form, the same examiner recorded the patient's history and performed a physical examination. An appropriate regimen of physiotherapy was tried first for most patients. Indication for surgical treatment after failed physiotherapy was made for 58 shoulders in 58 patients (27 women, 31 men) and was based on the results from physical examination, MRI (available in 220 of 350 cases), and plain radiographs. Sonographic findings were not used for decision-making; in particular, no patient was excluded from surgical treatment because of a negative sonographic finding. The median patient age was 52 years (range, 17–78 years). Thirty-seven patients underwent surgery on the right shoulder, 21 on the left shoulder. The median interval between sonography and surgery was 10 weeks (range, 0–50 weeks).

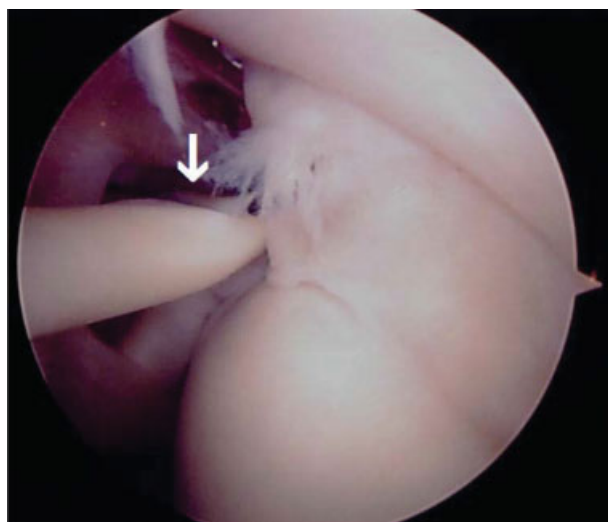


FIGURE 2. Arthroscopic photograph shows a grade I partial-thickness tear according to Ellman.²⁰ A probe (arrow) is introduced via the anterior approach, palpating the depth of the tear.

Arthroscopic surgery by way of subacromial decompression was indicated for 34 patients with symptoms typical of subacromial impingement (painful arc, positive Neer's or/and Hawkin's test, positive Neer's sign).^{18,19} Additional debridement was performed for partial-thickness tears. Arthroscopic debridement and decompression was performed in patients with symptoms from a full-thickness tear, as confirmed on MRI, when the tear was considered irreparable and in patients with low shoulder demands (6 patients). Open repair was indicated whenever a tear was considered reparable (18 patients).

All arthroscopic operations were performed by a single experienced surgeon (S.H.), other than the sonologist, who was blinded to the sonographic findings. Both the articular and bursal side of the rotator cuff were examined. Partial-thickness tears were palpated with a probe with a 3-mm right-angle arm (Figure 2) and classified according to Ellman²⁰ as grade I (<3 mm deep), grade II (3–6-mm deep), or grade III (>6 mm deep). The Location of the tears (regarding which tendons of the cuff were affected) was determined. Extension into the subscapularis was stated if there was visible damage of the tendinous part of the muscle. Extension into the infraspinatus was stated if a tear affected fibers coming from a level inferior to the scapular spine.²¹

In all open operations, the sonographic findings were available to the surgeon. In these cases, evaluation of the rotator cuff, measurement of tear size in the anterior–posterior and medial–lateral plane, and assessment of tear localization was performed by the assistant sur-

TABLE 1
Final Diagnosis at Surgery (More than 1 Diagnosis Possible per Patient) in 58 Patients

Diagnosis	No. of Patients
Impingement syndrome	20
Partial-thickness tear grade I (7 A, 2 B)	9
Partial-thickness tear grade II (1 A, 1 B)	2
Partial-thickness tear grade III (2 A, 1 B)	3
Full-thickness tear of the rotator cuff	24
Os acromiale	1
SLAP lesion grade 1	6

Abbreviations: A, articular side; B, bursal side; SLAP, superior labrum anterior–posterior.

geon who was blinded to the sonographic findings. Tear size measurement was performed with a sterile ruler and only in the case of open surgery. The final diagnoses at surgery are given in Table 1.

Statistical analysis was performed on the raw data presented in Table 2. Sensitivity, specificity, and predictive values for the diagnosis of a rotator cuff tear were calculated once by considering full-thickness tears as the positive finding and a second time by considering both full-thickness and partial-thickness tears as the positive finding. The 95% confidence intervals were derived from the binominal distribution (<http://members.aol.com/johnp71/confint.html>). For tear size measurement, the coefficient of variation and the 95% limits of agreement²² for the differences between the results from sonography and surgery are given.

RESULTS

Table 2 shows the correlation between the sonographic and surgical findings. All 24 cases with a surgically confirmed full-thickness tear, and 19 of 20 cases with a surgical finding of “no tear” were diagnosed correctly on sonography. For partial-thickness tears, all 9 grade I tears, both grade II tears, and 2 of 3 grade III tears were missed. One grade III tear was misinterpreted as a full-thickness tear. In 1 case, sonography diagnosed a partial-thickness tear that was not confirmed at surgery.

Table 3 shows the diagnostic accuracy values along with the 95% confidence intervals, separately considering full-thickness tears and both full- and partial-thickness tears as the positive finding.

Size of the Tear

For the anterior–posterior plane, 16 sonographic tear size measurements could be compared with

SONOGRAPHY OF THE ROTATOR CUFF

TABLE 2
Correlation between Sonographic and Surgical Findings in the Diagnosis of Rotator Cuff Tears in 58 Patients

Sonographic Findings	Surgical Findings					Total
	FTT	PTT Grade I	PTT Grade II	PTT Grade III	NT	
FTT	24	0	0	1	0	25
PTT	0	0	0	0	1	1
NT	0	9	2	2	19	32
Total	24	9	2	3	20	58

Abbreviations: FTT, full-thickness tear; NT, no tear; PTT, partial-thickness tear.

TABLE 3
Results of Sonographic Diagnosis of Full-Thickness versus Partial-Thickness/No Tear and of Full/Partial-Thickness versus No Tear

	FTT versus PTT and NT (95% CI)	FTT and PTT versus NT (95% CI)
Sensitivity (%)	100 (100–88)	66 (80–49)
Specificity (%)	97 (100–85)	95 (100–75)
PPV (%)	96 (100–80)	96 (100–80)
NPV (%)	100 (100–91)	59 (76–41)

Abbreviations: FTT, full-thickness tear; NPV, negative predictive value; NT, no tear; PPV, positive predictive value; PTT, partial-thickness tear.

results from open surgery. For the medial–lateral plane, this was possible only in 14 cases (in 2 cases, the torn end of the rotator cuff could not be visualized distal to the acromion and was classified as not visible) (Table 4). For individual measurements, the 95% range of agreement was -2.6 ± 9.8 mm in the anterior–posterior plane, and -3.4 ± 9.9 mm in the medial–lateral plane. The coefficient of variation was 16.5% and 20% for measurements in the anterior–posterior and in the medial–lateral plane, respectively.

Location of the Tear

Location of the tear was described correctly on sonography in 21 of 25 cases. Eleven tears were limited to the supraspinatus tendon; 7 affected the tendons of the supraspinatus and infraspinatus; 1 affected the tendons of the supraspinatus, infraspinatus, and subscapularis; and 2 were isolated tears of the subscapularis. All 21 tears located correctly on sonography were found to be full-thickness tears at surgery.

In 3 of 4 cases with an incorrect description of location, isolated supraspinatus tears were found on sonography, whereas combined supraspinatus and infraspinatus tears were found at surgery. In the fourth case with a sonographic diagnosis of a partial tear in the subscapularis tendon together with a full-thickness tear in the supraspinatus, only a grade III partial-thickness tear in the supraspinatus tendon was detected at surgery.

DISCUSSION

It has been demonstrated that sonography can give valuable information when pathology of the rotator cuff is suspected. Several studies have shown high sensitivity and specificity for detection of full-thickness tears in the rotator cuff.^{1–7} Measurement of the tear size and description of the location with respect to the rotator cuff tendons have been performed successfully.^{1,23} In these studies, sonography was used together with clinical information, which might have biased the results. As Murell and Walton⁸ and Litaker et al.⁹ have shown, rotator cuff tears can be diagnosed clinically with high sensitivity and specificity in the subgroup of patients presenting with the 4 classical clinical signs: shoulder pain, supraspinatus weakness, weakness of external rotation, and positive impingement sign. Wolf and Agrawal¹⁰ and Lyons and Tomlinson¹¹ found high diagnostic accuracy for transdeltoid palpation of the rotator cuff (rent test).

Few articles focus on sonography as an isolated diagnostic technique for the rotator cuff. Iannotti et al.²⁴ found an accuracy of 52% for the blinded interpretation of sonography compared with 80% when its interpretation was combined with clinical information. In this study, however, surgery and interpretation of sonography with knowledge of clinical information were performed by the same operator. Teefey et al.²⁵ achieved an accuracy of 94% for the detection of rotator cuff tears via sonography, but the criterion of inclusion of “high clinical suspicion of rotator cuff disease” provided clinical information to the otherwise blinded sonologist.

In our study, we tried to eliminate the possibility of interpretation bias. The presence of a painful shoulder was the only clinical information given to the sonologist, who was blinded to any other medical history data as well as the results of physical examination and other imaging tests. Furthermore, for arthroscopic operations, the influence of sonographic findings on intraoperative interpretation was eliminated by blinding the surgeon to the findings. Our results show

TABLE 4
Tear Size in Anterior–Posterior and Medial–Lateral Planes Measured via Sonography during Open Surgery

Patient No.	Anterior–Posterior Plane (mm)			Medial–Lateral Plane (mm)		
	US	OP	Diff.	US	OP	Diff.
1	23	30	–7	20	20	0
2	50	50	0	NV*	50*	–
3	13	15	–2	19	20	–1
4	16	20	–4	12	20	–8
5	8	15	–7	8	20	–12
6	14	12	2	12	5	7
7	19	20	–1	20	20	0
8	5	5	0	7	6	1
9	20	12	8	22	25	–3
10	8	20	–12	11	15	–4
11	50	50	0	NV*	50*	–
12	20	25	–5	15	20	–5
13	15	25	–10	20	25	–5
14	30	30	0	25	30	–5
15	10	10	0	13	30	–7
16	14	18	–4	18	14	4
Mean	19.7	22.3	–2.6	15.9	19.3	–3.4
SD	–	–	4.91	–	–	4.97

Abbreviations: Diff., difference between distances measured on sonography and at open surgery; NV, not visible, OP, open surgery; US, sonography.
 * Values excluded from calculation of the mean and SD.

that sonography used as an isolated diagnostic technique is accurate in the detection of full-thickness tears of the rotator cuff. Our values for sensitivity and specificity are comparable to results of studies in which sonography was used as part of the diagnostic process.^{1–7} On the other hand, our results regarding the detection of partial-thickness tears are poor. Earlier papers show that success in detecting partial-thickness tears is lower than for full-thickness tears and varies substantially among institutions. Different groups have published results with sensitivity and specificity values ranging from 13% to 93% and from 20% to 94%, respectively.^{13,26–28} In our series, 13 of 14 partial-thickness tears were not diagnosed via sonography, and 1 was misinterpreted as a full-thickness tear. There may be several explanations for this poor performance. Because sonographic identification of partial-thickness tears can be fairly subjective, bias from clinical information may have a stronger impact on the interpretation of sonographic findings of these tears, making it more difficult for the blinded examiner to reach a correct diagnosis. Use of higher transducer frequencies (10–13 MHz) and more advanced equipment with tissue harmonic imaging also might have improved our results.

Finally, these results may be explained by the high proportion of superficial partial-thickness tears in our study. Decrease in sensitivity of sonography for smaller lesions has been shown by Bachmann et al.²⁹ and by Ferrari et al.⁶ Nine of the overlooked partial-thickness tears were classified as a grade I intraoperatively, 2 as a

grade II. Because the initial treatment options are similar for intact rotator cuffs and partial tears of grade I or II, the clinical consequences are small if these tears are overlooked. It therefore seems justified to regard our results for full-thickness tears versus partial-thickness tears and no tears as the most relevant.

For partial-thickness tears of grade III, diagnostic confirmation is important, because these tears should be considered for tendon repair. The low number of grade III tears in our study does not allow conclusions about the diagnostic value of sonography for these lesions. Preoperative knowledge of rotator cuff tear size and location is important in planning treatment and advising patients regarding prognosis and outcome. Tear size is crucial for the difficulty of the repair, with a better prognosis for smaller tears.^{30,31} In accordance with other studies, we found that sonography tends to underestimate the size of rotator cuff tears.^{1,17,32} For a mean difference of 2.6 and 3.4 mm in the 2 planes (Table 4), the 95% range of agreement for individual measurements of approximately ± 1 cm is fairly large. However, we believe that the sonographic measurement of the tear size is still adequate for the purpose of planning the surgical approach.

Just as important for preoperative planning as tear size is the location of the tear with respect to the rotator cuff tendons. Surgical approaches should be selected in accordance with the location of the lesion. We operate on tears with a superior–posterior extension using a deltoid splitting approach, on tears extending into the subscapularis

using the approaches described by Mackenzie³³ or Warner et al.,³⁴ and on isolated subscapularis tears using a delto-pectoral approach. Selection of the most appropriate approach on the basis of sonographic findings was possible in 24 of 25 cases in this study.

Several limitations in our study design should be discussed. A bias was introduced by the orthopedist's selection of surgical versus nonsurgical candidates. Surgery was performed in only 58 of the 350 cases. The majority of the remaining patients underwent successful conservative treatment, and a definitive diagnostic confirmation is not available. Sixty-three of the 292 conservatively treated patients showed a full-thickness tear on sonography, 30 showed a partial-thickness tear, and an intact rotator cuff was found in 199 cases. MRI findings were available for 178 of the nonoperative patients. The majority of the MRI examinations were performed before referral to the hospital in a nonstandardized manner (at different radiologic institutes, following different examination protocols). It was therefore not possible to use these results as a reference for the nonoperative group.

Blinding for clinical examination findings might have been incomplete, because the sonographer could have a sense of the patient's pain during the dynamic part of the examination. However, in our experience the only painful part of the sonographic examination occurs when the arm is moved in adduction and internal rotation in the patient's back. We believe that this pain is nonspecific and cannot help the examiner differentiate between a torn and an intact rotator cuff.

In conclusion, sonography provides valuable information about the condition of the rotator cuff, even when used as an isolated technique. After exclusion of bias from the patient's history and physical examination findings, the sensitivity and specificity were excellent for full-thickness tears but poor for partial-thickness tears. Description of the location of the full-thickness tears was possible with sufficient precision to be used as a guide to surgical approach. Sonographic measurement of tear size was possible in most cases but gave only an estimate of the actual gap.

REFERENCES

1. Farin PU, Kaukanen E, Jaroma H, et al. Findings at ultrasound, double-contrast arthrography, and computed tomography arthrography with surgical correlation. *Invest Radiol* 1996;31:387.
2. Sonnabend DH, Hughes JS, Giuffre BM, et al. The clinical role of shoulder ultrasound. *Aust NZ J Surg* 1997;67:630.
3. Read JW, Perko M. Shoulder ultrasound: diagnostic accuracy for impingement syndrome, rotator cuff tear, and biceps tendon pathology. *J Shoulder Elbow Surg* 1998;7:264.
4. Teefey SA, Hasan SA, Middleton WD, et al. Ultrasonography of the rotator cuff. *J Bone Joint Surg Am* 2000;82:498.
5. Roberts CS, Walker JA, Seligson D. Diagnostic capabilities of shoulder ultrasonography in the detection of complete and partial rotator cuff tears. *Am J Orthop* 2001;30:159.
6. Ferrari FS, Governi S, Burrelli F, et al. Supraspinatus tendon tears: comparison of US and MR arthrography with surgical correlation. *Eur Radiol* 2002;12:1211.
7. Ziegler DW. The use of in-office, orthopaedist-performed ultrasound of the shoulder to evaluate and manage rotator cuff disorders. *J Shoulder Elbow Surg* 2004;13:291.
8. Murell GA, Walton JR. Diagnosis of rotator cuff tears. *Lancet* 2001;357:769.
9. Litaker D, Pioro M, El Bilbeisi H, et al. Returning to the bedside: using the history and physical examination to identify rotator cuff tears. *J Am Geriatr Soc* 2000;48:1633.
10. Wolf EM, Agrawal V. Transdeltoid palpation (the rent test) in the diagnosis of rotator cuff tears. *J Shoulder Elbow Surg* 2001;10:470.
11. Lyons AR, Tomlinson JE. Clinical diagnosis of tears of the rotator cuff. *J Bone Joint Surg Br* 1992;74:414.
12. Moosmayer S, Smith HJ. Diagnostic ultrasound of the shoulder—a method for experts only? Results from an orthopedic surgeon with relative inexperience compared to operative findings. *Acta Orthop* 2005;76:503.
13. van Holsbeeck MT, Kolowich PA, Eyler WR, et al. US depiction of partial-thickness tear of the rotator cuff. *Radiology* 1995;197:443.
14. Middleton WD, Teefey SA, Yamaguchi K. Sonography of the shoulder. *Semin Musculoskelet Radiol* 1998;2:211.
15. Bouffard JA, Lee S-M, Dhanju J. Ultrasonography of the shoulder. *Semin Ultrasound* 2000;21:164.
16. Wiener SN, Seitz WH. Sonography of the shoulder in patients with tears of the rotator cuff: accuracy and value for selecting surgical options. *AJR Am J Roentgenol* 1993;160:103.
17. Zehetgruber H, Lang T, Wurnig C. Distinction between supraspinatus, infraspinatus and subscapularis tendon tears with ultrasound in 332 surgically confirmed cases. *Ultrasound Med Biol* 2002;28:711.
18. Neer CS. Impingement lesions. *Clin Orthop Relat Res* 1983;173:70.
19. Hawkins RJ, Kennedy JC. Impingement syndrome in athletes. *Am J Sports Med* 1980;8:151.
20. Ellman H. Diagnosis and treatment of incomplete rotator cuff tears. *Clin Orthop Relat Res* 1990;254:64.
21. Gerber C, Fuchs B, Hodler J. The results of repair of massive tears of the rotator cuff. *J Bone Joint Surg Am* 2000;82:505.

22. Altman DG. Some common problems in medical research. In: Altman DG, editor. *Practical statistics for medical research*. London: Chapman & Hall; 1999. p 396.
23. Kluger R, Mayrhofer R, Kröner A, et al. Sonographic versus magnetic resonance arthrographic evaluation of full-thickness rotator cuff tears in millimeters. *J Shoulder Elbow Surg* 2003;12:110.
24. Iannotti JP, Ciccone J, Buss DD, et al. Accuracy of office-based ultrasonography of the shoulder for the diagnosis of rotator cuff tears. *J Bone Joint Surg Am* 2005;87:1305.
25. Teefey SA, Rubin DA, Middleton WD, et al. Detection and quantification of rotator cuff tears. *J Bone Joint Surg Am* 2004;86:708.
26. Kenn W, Hufnagel P, Müller T, et al. Arthrography, ultrasound and MR imaging in the evaluation of the rotator cuff: a prospective study [in German]. *Fortschr Röntgenstr* 2000;172:260.
27. Martín-Hervás C, Romero J, Navas-Acién A, et al. Ultrasonographic and magnetic resonance images of rotator cuff lesions compared with arthroscopy or open surgery findings. *J Shoulder Elbow Surg* 2001;10:410.
28. Wu HP, Dubinsky TJ, Richardson ML. Association of shoulder sonographic findings with subsequent surgical treatment for rotator cuff injury. *J Ultrasound Med* 2003;22:155.
29. Bachmann GF, Melzer C, Heinrichs CM, et al. Diagnosis of rotator cuff lesions: comparison of US and MRI on 38 joint specimens. *Eur Radiol* 1997;7:192.
30. Gore DR, Murray MP, Sepic SB, et al. Shoulder-muscle strength and range of motion following surgical repair of full-thickness rotator-cuff tears. *J Bone Joint Surg Am* 1986;68:266.
31. Iannotti JP, Bernot MP, Kuhlman JR, et al. Post-operative assessment of shoulder function: a prospective study of full-thickness rotator cuff tears. *J Shoulder Elbow Surg* 1996;5:449.
32. Bryant L, Shnier R, Bryant C, et al. A comparison of clinical estimation, ultrasonography, magnetic resonance imaging, and arthroscopy in determining the size of rotator cuff tears. *J Shoulder Elbow Surg* 2002;11:219.
33. Mackenzie DB. The antero-superior exposure for total shoulder replacement. *Orthop Traumatol* 1993;2:71.
34. Warner JJ, Higgins L, Parsons IM, et al. Diagnosis and treatment of anterosuperior rotator cuff tears. *J Shoulder Elbow Surg* 2001;10:37.